

THE JOURNAL OF BONE & JOINT SURGERY

J B & J S

This is an enhanced PDF from The Journal of Bone and Joint Surgery

The PDF of the article you requested follows this cover page.

Surgical Treatment of Degenerative Disease of the Back

BENJAMIN R. WILTBERGER

J Bone Joint Surg Am. 1963;45:1509-1516.

This information is current as of April 12, 2008

Reprints and Permissions

Click here to [order reprints or request permission](#) to use material from this article, or locate the article citation on jbjs.org and click on the [Reprints and Permissions] link.

Publisher Information

The Journal of Bone and Joint Surgery
20 Pickering Street, Needham, MA 02492-3157
www.jbjs.org



Surgical Treatment of Degenerative Disease of the Back

BY BENJAMIN R. WILTBERGER, M.D.*, COLUMBUS, OHIO

An Instructional Course Lecture, The American Academy of Orthopaedic Surgeons

With the gradual evolution of a more comprehensive understanding of low-back pain, one comes to realize that it is most often a consequence of a progressive degenerative process of the lower lumbar portion of the spine. Degeneration of the intervertebral disc or of other structures causes a deformity which results in decompensation of the spine as a unit, each anatomical part affecting others. Some of the relationships are illustrated in Figures 1, 2, and 3, and most commonly the disc space may narrow and displace the vertebral body, causing nerve-root compression and degenerative changes in the articular processes.

The conservative treatment described by Davis uses the surgical principle of compensating by flexion of the lower portion of the back to preserve the size of the neural foramen.

With the same rationale, it is generally agreed that most successful spine fu-

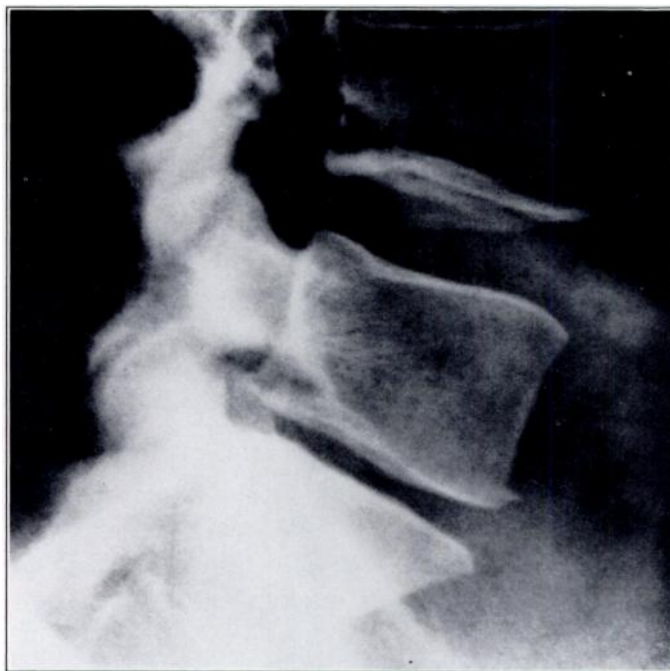

FIG. 1
Degenerated lumbosacral joint.

* Ohio State University College of Medicine, Department of Surgery, Division of Orthopaedic Surgery, Columbus, Ohio.

sions for low-back pain must be done with the view of maintaining distraction of vertebrae^{1,2,3,4,7,10}.

In spite of the increased morbidity when spine fusion is performed after removal of a herniated nucleus pulposus, use of the procedure is increasing among surgeons who do a considerable amount of spine surgery. Observations to this effect were made by Young and Love and Stinchfield and Cruess in the Instructional Course Lectures in 1959 and 1961, respectively.

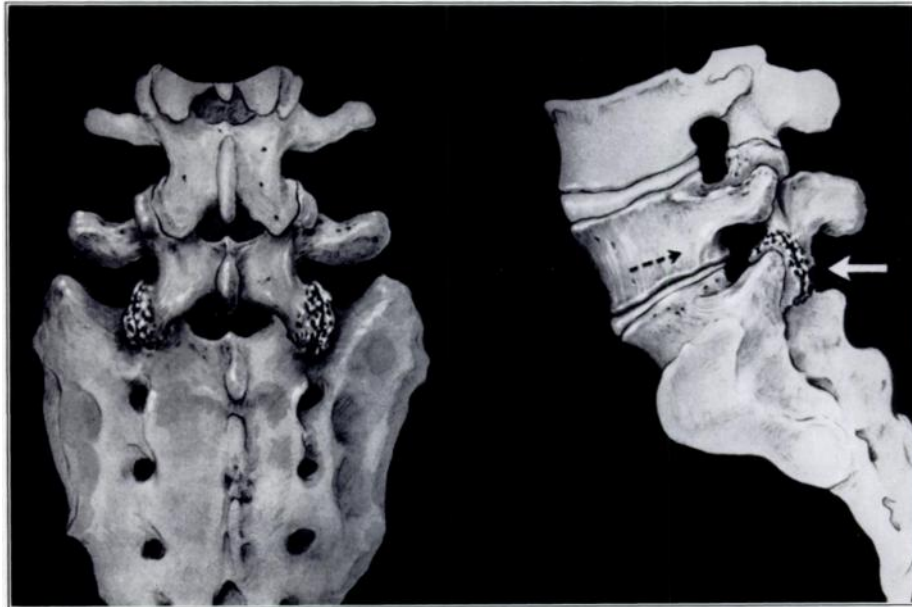


FIG. 2

Degenerative changes of disc and articular processes.

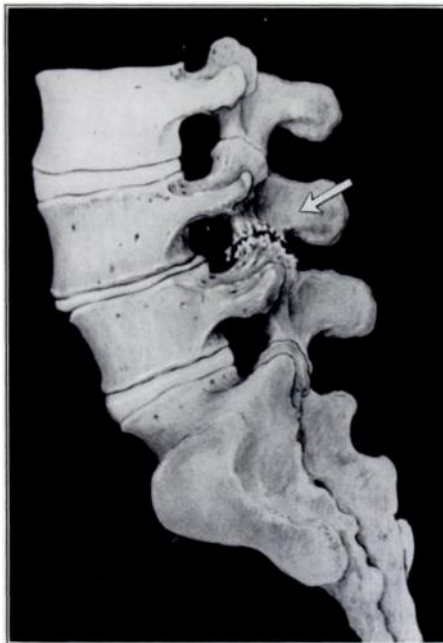

FIG. 3

Pseudospondylolisthesis.

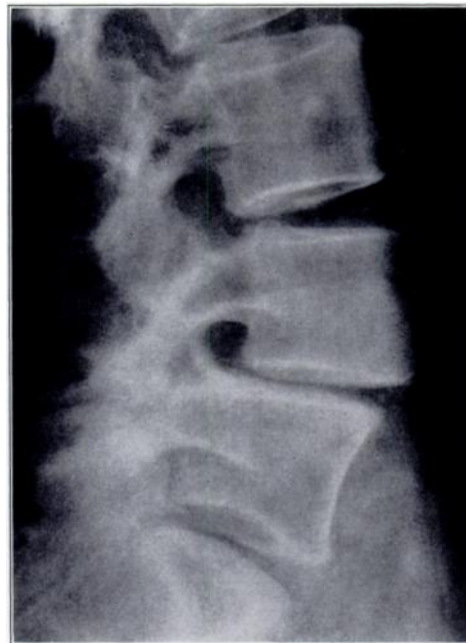

FIG. 4

Pseudospondylolisthesis.

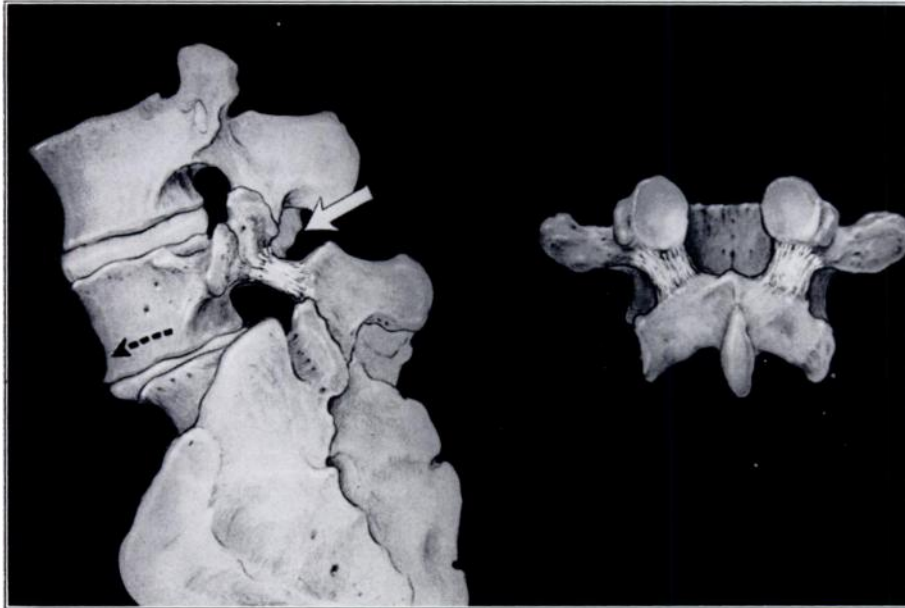


FIG. 5

Spondylolisthesis with pedicle defect.

Indications for Fusion

Fusion may be indicated for:

1. A narrowed disc space causing deterioration of the articular processes with either forward or backward positioning of the superior vertebra on the one below and encroachment on the neural foramen (Figs. 1 through 4);
2. Spondylolisthesis (Fig. 5);
3. Congenital anomalies such as hemivertebra or sacralization of a vertebra (Fig. 6);
4. Failure of relief of pain from a previous laminectomy;
5. Symptomatic non-union of a spine fusion (Fig. 7);
6. Other factors secondary to degeneration of the intervertebral disc such as a laterally trapped nerve, epidural encirclement, or a vicious form of the reflex vascular phenomenon;
7. Old healed compression fractures with secondary radiculitis and arthritis (Fig. 8);
8. Herniation of the nucleus pulposus in heavy laborers and non-skilled workers who do not change occupation to skilled light work.

Contra-Indications to Spine Fusion

Spine fusion is contra-indicated in:

1. Marked arteriosclerosis;
2. Minimum degenerative change or congenital anomaly in skilled workers not performing heavy labor;
3. Some cardiovascular diseases;
4. Psychosomatic overlay when increased morbidity might precipitate a true psychosis;
5. Obesity;
6. Other widespread evidence of degenerative skeletal change;
7. Pending litigation or compensation which tends to perpetuate all forms of backache.

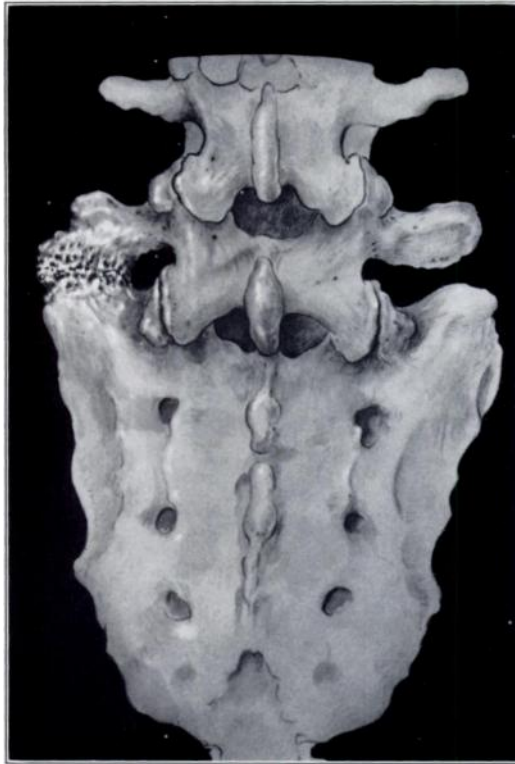

FIG. 6
Congenital sacralization.

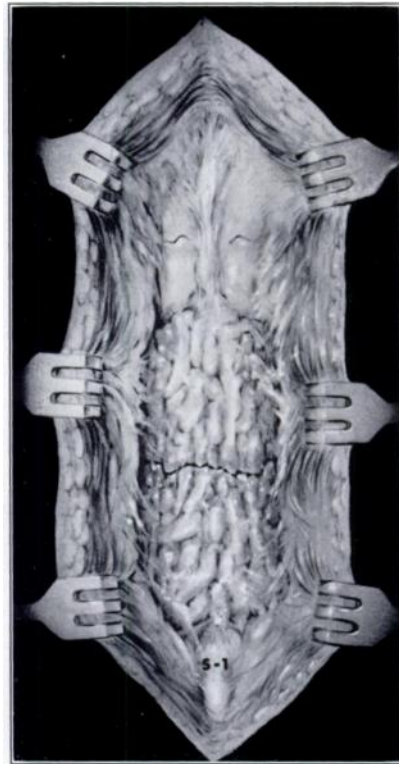

FIG. 7
Non-union of posterior fusion.

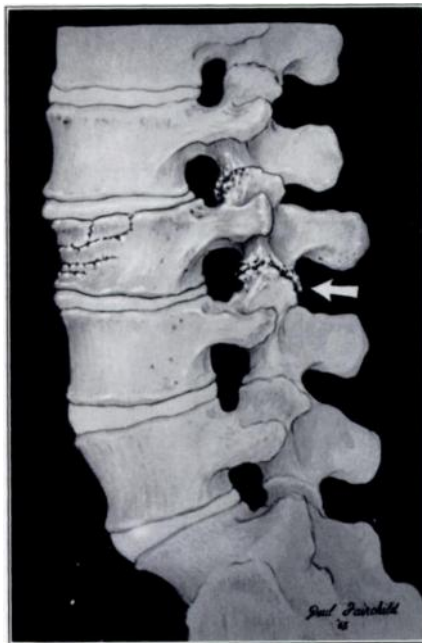

FIG. 8
Fracture with traumatic arthritis.

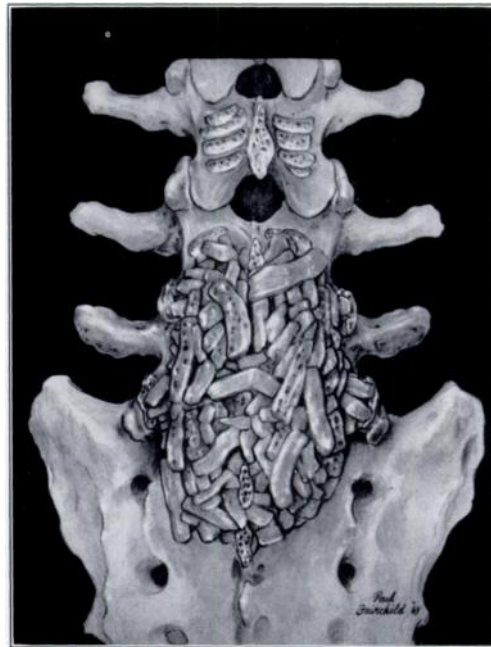

FIG. 9
Hibb's fusion.

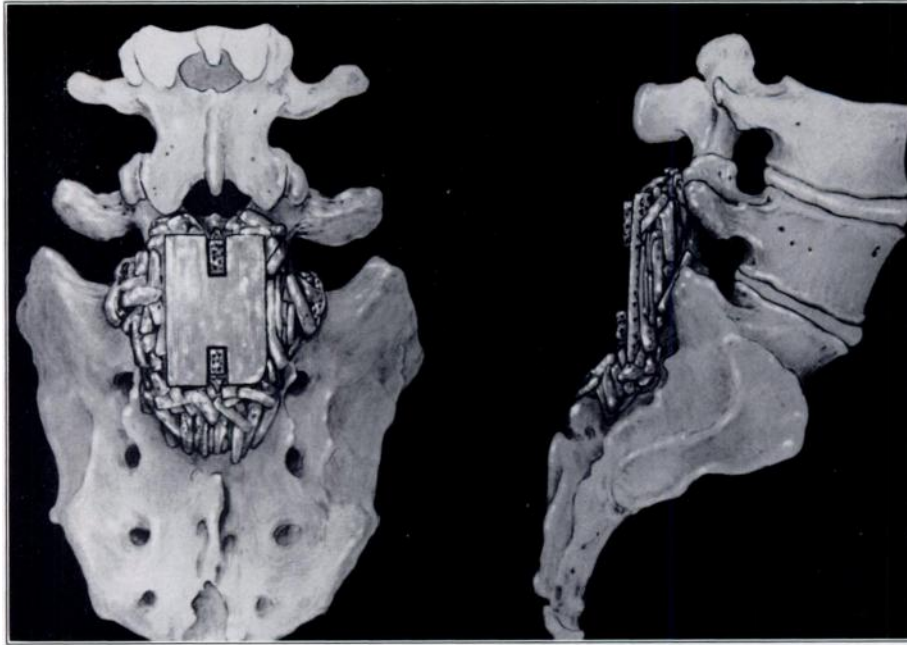


FIG. 10
Bosworth's fusion.

Degenerative disease of the back may be treated surgically either by conventional fusions of the posterior elements (Figs. 9 and 10) or by the more recently developed interbody fusions (Figs. 11 and 12). In certain cases, such as third-degree spondylolisthesis, bilateral transverse process fusion is indicated. The different surgical techniques are well described in current orthopaedic journals and textbooks.

The advantage of fusion of the posterior elements over interbody fusion is its simplicity. Its disadvantages are that motion can occur anterior to the fusion site by springing of the fusion from elasticity of bone and that surgical re-entry, if required, is quite difficult and may be hazardous.

The advantage of the vertebral body fusion is that when it is technically and properly performed it is less traumatic. Furthermore, the back can be explored, if necessary, posteriorly with ease. All vertebral body fusions distract the vertebral bodies and use the normal compression forces of weight-bearing to aid union. This conforms to Eggers' principle of compression as an aid to repair. The disadvantages of vertebral body fusions are that the surgical techniques are more difficult to learn, and if they are not done accurately the operation is hazardous.

Well intentioned efforts to cure back pain by operation, create, under some circumstances, the distressing new problem of "surgical back cripple." Dr. Ralph Ghormley dedicated the latter part of his life to our education in the prevention and treatment of this clinical condition. I believe the condition has several distinct causes:

1. In many instances we have operated on psychiatrically sick patients or have relied on surgery for the treatment of psychosomatic problems;
2. Frequently simple laminectomy proves to be inadequate surgery and perhaps years later compression of the neural foramen and traumatic arthritis of the articular processes appear (Figs. 1 and 2);
3. We all have had the experience of finding a newly ruptured disc at a level different from that of the original operation or under a solid posterior fusion;

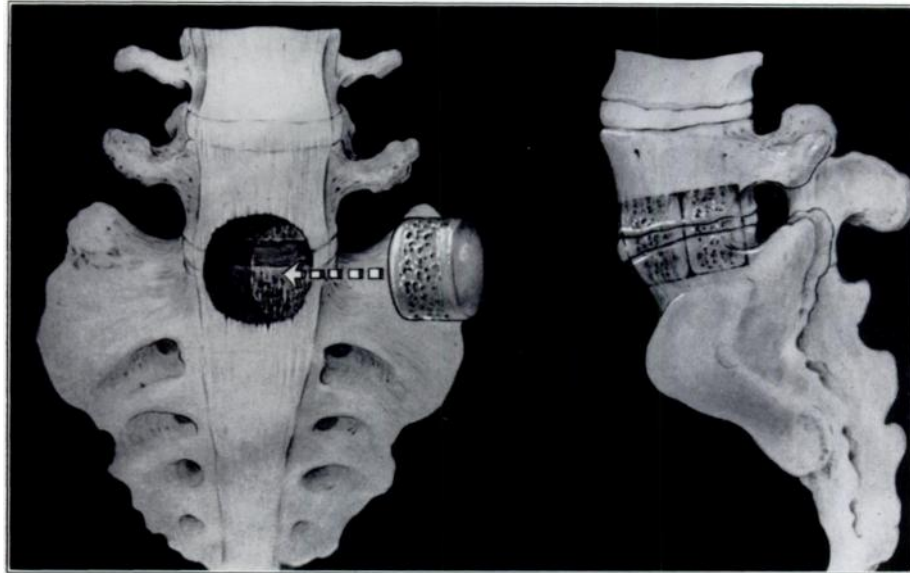


FIG. 11
Vertebral body fusion, anterior approach.

4. There is always the possibility of non-union in any type of fusion or following fracture of a once-solid fusion (Fig. 7). Causalgia of the cauda equina nerve roots, as described by Freeman, or the constant pulling by massive adhesions about the nerve roots may be the cause of constant low back and leg pain.

Of course, patients having different reasons for being "surgical back cripples" must be treated differently according to the cause or causes of these difficulties. Obesity requires dieting or psychological therapy or both. The psychiatrically sick patient may need tranquilizers and psychotherapy. Patients with pain from adhesions and minor causalgia of the legs may be helped by intravenous procaine hydrochloride (one gram in 1000 milliliters of 5 per cent glucose in sterile water)

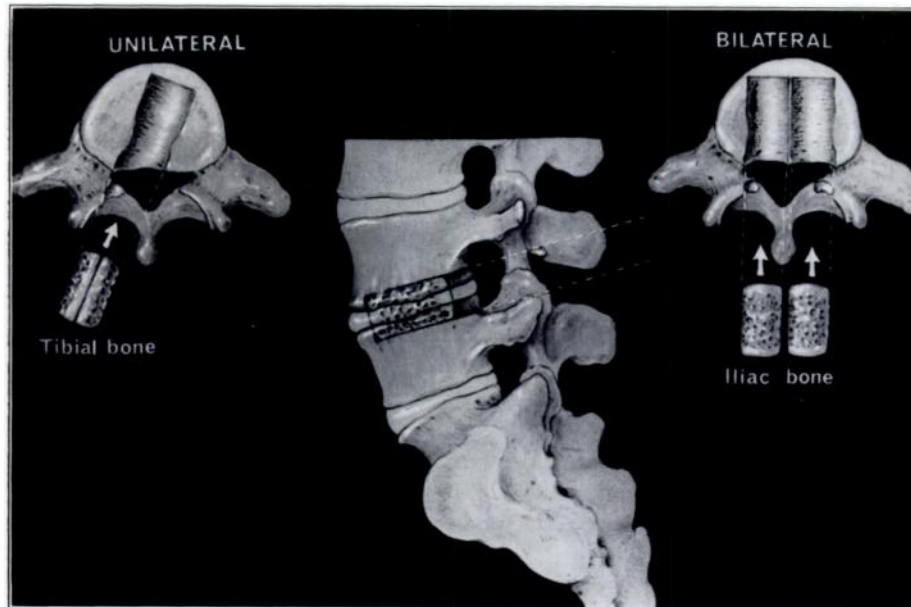


FIG. 12
Vertebral body fusion, posterior approach.

given daily over a two-hour period. If the pain is intense, it may be necessary to give a series of six daily caudal blocks of forty milliliters of 0.5 per cent procaine hydrochloride with two milliliters of hydrocortisone acetate, followed by repeated straight-leg stretching to 90 degrees. Quinine sulphate (five grains) often stops leg cramps due to circulatory disorders. In any case, the "surgical back cripple" should not be given narcotics but should be maintained on analgesics every four hours with milk or food.

If cyanosis and coldness of the leg accompany causalgia, sympathectomy, as advocated by Freeman, may be necessary, or simple rhizotomy of the dorsal element of a single nerve root may help.

New or previously undiscovered ruptured discs should be excised, as should recurrent ruptured discs. Fractures or non-union of bone grafts should be repaired.

Comment

When the degenerative back fails to compensate after a thorough trial of conservative treatment, it must be treated surgically. As with other persistently painful joints, some form of arthrodesis must be done since no successful arthroplasty has been perfected to date, including the attempt by Nachemson to replace a degenerative disc with silicone rubber.

Summary

Arthrodesis is at present the best surgical treatment for the persistently painful degenerative back. However, it increases the morbidity and mortality rate in spine surgery, and the possibility of non-union is always present.

Primary arthrodesis in lumbar-disc surgery increases the percentage of successful results. If only the disc is removed, three times as many failures to obtain relief from pain may be expected as when fusion is also performed¹¹.

In my opinion, the best fusion is the one the surgeon is most skillful in performing, unless some extraordinary circumstance indicates that another type of fusion would be preferable.

One should try to fuse the spine in distraction, if possible, in an attempt to open the neural foramen.

It is wise to limit the arthrodesis to as few interspaces as possible, as it has been established that the non-union rate rises dramatically as the number of interspaces involved increases.

References

1. BOSWORTH, D. M.: Technique of Spinal Fusion in the Lumbosacral Region by the Double Clothspin Graft (Distraction Graft; "H" Graft) and Results. *In* Instructional Course Lectures, The American Academy of Orthopaedic Surgeons. Vol. 9, pp. 44-52. Ann Arbor, J. W. Edwards, 1952.
2. BRECK, L. W., and BASOM, W. C.: The Flexion Treatment for Low-Back Pain. Indications, Outline of Conservative Management, and a New Spine-Fusion Procedure. *J. Bone and Joint Surg.*, **25**: 58-64, Jan. 1943.
3. CLOWARD, R. B.: Changes in the Vertebra Caused by Ruptured Intervertebral Discs. Observations on Their Formation and Treatment. *Am. J. Surg.*, **84**: 151-161, 1952.
4. CLOWARD, R. B.: Recent Improvements in the Surgical Treatment of Low-Back Pain Due to Ruptured Lumbar Intervertebral Discs. *Hawaii Med. J.*, **11**: 279-285, 1952.
5. DAVIS, J. B.: The Degenerative Back. Instructional Course Lecture No. 4, The American Academy of Orthopaedic Surgeons, Miami Beach, Florida, January 21, 1963.
6. FREEMAN, L. W.: Surgical Treatment of Back and Leg Pain Persisting after Adequate Disc Surgery. *J. Indiana Med. Assn.*, **54**: 1265-1267, 1961.
7. HARMON, P. C.: Anterior Extraperitoneal Lumbar Disk Excision and Vertebral Body Fusion. *Clin. Orthop.*, **18**: 169-198, 1960.
8. NACHEMSON, ALF: Some Mechanical Properties of the Lumbar Intervertebral Discs. *Bull. Hosp. Joint Dis.*, **23**: 130-143, 1962.
9. STINCHFIELD, F. E., and CRUESS, R. L.: Indications for Spine Fusion in Conjunction with Removal of Herniated Nucleus Pulposus. *In* Instructional Course Lectures, The American Academy of Orthopaedic Surgeons. Vol. 18, pp. 41-45. St. Louis, The C. V. Mosby Co., 1961.

10. WILTBERGER, B. R.: The Dowel Intervertebral-Body Fusion as Used in Lumbar-Disc Surgery. *J. Bone and Joint Surg.*, **39-A**: 284-292, Apr. 1957.
11. YOUNG, H. H., and LOVE, J. G.: End Results of Removal of Protruded Lumbar Intervertebral Discs with and without Fusion. *In Instructional Course Lectures, The American Academy of Orthopaedic Surgeons*. Vol. 16, pp. 213-216. St. Louis, The C. V. Mosby Co., 1959.